

---

[All ETDs from UAB](#)

[UAB Theses & Dissertations](#)

---

2007

## A Reevaluation of Mandibular Intercanine Dimension and Incisal Position

Kelly R. Page

Follow this and additional works at: <https://digitalcommons.library.uab.edu/etd-collection>

---

### Recommended Citation

Page, Kelly R., "A Reevaluation of Mandibular Intercanine Dimension and Incisal Position" (2007). *All ETDs from UAB*. 6721.

<https://digitalcommons.library.uab.edu/etd-collection/6721>

This content has been accepted for inclusion by an authorized administrator of the UAB Digital Commons, and is provided as a free open access item. All inquiries regarding this item or the UAB Digital Commons should be directed to the [UAB Libraries Office of Scholarly Communication](#).

A REEVALUATION OF MANDIBULAR INTERCANINE DIMENSION  
AND INCISAL POSITION

by

KELLY R. PAGE

P. LIONEL SADOWSKY, COMMITTEE CHAIR  
ALEXANDER JACOBSON  
FIROZ RAHEMTULLA

A THESIS

Submitted to the graduate faculty of The University of Alabama at Birmingham,  
in partial fulfillment of the requirements for the degree of Master of Science

BIRMINGHAM, ALABAMA

2007

A REEVALUATION OF MANDIBULAR INTERCANINE DIMENSION  
AND INCISAL POSITION

KELLY R. PAGE

GRADUATE SCHOOL, UNIVERSITY OF ALABAMA AT BIRMINGHAM

ABSTRACT

The purpose of the present study was to compare a sample of patients with borderline mandibular crowding of 4 to 8 mm (measured on electronic models) that could benefit from extraction therapy or nonextraction therapy. Sixty patients treated by orthodontic residents at The University of Alabama School of Dentistry Department of Orthodontics were evaluated. Thirty patients were treated with nonextraction, and 30 patients were treated with extraction of premolars (17 second premolars and 13 first premolars). Geodigm emodel software was used to compare mandibular width dimensional changes from pretreatment to after orthodontic treatment among the nonextraction, extraction of mandibular first premolar, and extraction of mandibular second premolar treatment groups. In addition, pretreatment and posttreatment cephalograms of the treatment groups were traced with Dolphin Imaging software and compared by evaluating the angle of the mandibular incisor in relation to the mandibular plane. Results of the study showed more intercanine expansion in the extraction sample than in the nonextraction sample. However, the nonextraction sample had a large increase in incisor mandibular plane angle, whereas the extraction samples showed a decrease. The measurements that were statistically significantly different in the extraction and nonextraction groups were as follows:

1. Intercanine width measured at the gingival margin: the extraction sample showed more expansion than the nonextraction group did.

2. Second premolar width in nonextraction patients and first premolar extraction group: nonextraction sample showed expansion in the second premolar width, whereas the first premolar extraction sample showed constriction.
3. Intermolar width change in nonextraction and extraction groups: the nonextraction group showed slight expansion in the intermolar width, whereas the extraction groups showed constriction.
4. Incisor mandibular plane angle changes in nonextraction and extraction samples: the nonextraction group had a large increase in incisor mandibular plane angle, whereas the extraction samples showed a decrease.

## DEDICATION

To my wonderful husband, Greg, for his amazing ability to balance family and career while providing support and understanding to me during my residency. To my children, Jesse and Clayton, for their understanding of my time restraints and for all of the hugs and kisses.

## ACKNOWLEDGMENTS

I express sincere gratitude to the following persons:

to the members of my committee, Dr. P. Lionel Sadowsky, Dr. Alex Jacobson, and Dr. Firoz Rahemtulla, for their experience and guidance during this endeavor;

to the faculty members and staff for their patience and for their dedication to preparing me for a future in orthodontics;

to my fellow classmates and residents, with whom I have shared many wonderful experiences along this journey;

and to my family, whose constant love, support, and encouragement have been an inspiration to me. I am forever grateful to them all.

## TABLE OF CONTENTS

	<i>Page</i>
ABSTRACT.....	ii
DEDICATION.....	iv
ACKNOWLEDGMENTS.....	v
LIST OF TABLES.....	vii
LIST OF FIGURES.....	viii
INTRODUCTION.....	1
LITERATURE REVIEW.....	5
Facial Esthetics.....	5
Temporomandibular Joint.....	12
Mandibular Intercanine Dimension.....	15
Mandibular Incisor Axial Inclination.....	19
Retention and Stability.....	20
A REEVALUATION OF MANDIBULAR INTERCANINE DIMENSION AND INCISAL POSITION.....	28
CONCLUSIONS.....	52
GENERAL LIST OF REFERENCES.....	55
APPENDIX: INSTITUTIONAL REVIEW BOARD FOR HUMAN USE APPROVAL FORM.....	62

LIST OF TABLES

A REEVALUATION OF MANDIBULAR INTERCANINE DIMENSION  
AND INCISAL POSITION

<i>Table</i>		<i>Page</i>
1.	Descriptive Statistics: Sample Demographics.....	34
2.	Age Range of the Nonextraction and Extraction Sample Groups.....	35
3.	Change in Mandibular Arch Dimensions (From T1 – T2).....	40
4.	Mean IMPA Between Groups at T1 and T2.....	41



LIST OF FIGURES

A REEVALUATION OF MANDIBULAR INTERCANINE DIMENSION  
AND INCISAL POSITION

<i>Figure</i>		<i>Page</i>
1.	Scattergram comparing change in IMPA to initial mandibular crowding among the three treatment groups.....	38

## INTRODUCTION

The debate over extraction versus nonextraction therapy has been ongoing for decades. In the 1890s, the extraction of teeth was a popular orthodontic treatment option. Edward Angle agreed with other conservative dentists during this time that teeth should not be extracted for orthodontic purposes. It became his mission to preserve tooth structure in all instances. Angle believed that every person had the potential for an ideal relationship of all 32 natural teeth and that therefore, extraction of any teeth for orthodontic purposes was never needed.<sup>1</sup>

Angle based his nonextraction therapy beliefs upon two main concepts: First, that bone remodeled under stress, and different patterns of pressure could modify growth to overcome skeletal discrepancies. He believed that rubber bands from the maxilla to the mandible could correct skeletal jaw discrepancies because of the adaptability of the skeletal structures and the ability of functional forces to induce basal bone growth. The teeth, once positioned, would be surrounded by newly formed basal bone, thereby precluding extractions.<sup>1</sup> The second concept concerned retention. Angle argued that the key to maintaining a final stabilized orthodontic result was proper occlusion. He contended that proper occlusal forces would stabilize teeth in their new position. He searched for a technique to move teeth bodily instead of tipping teeth to their new position and described his edgewise appliance as a “bone growing appliance.”<sup>2</sup> Angle attributed relapse to the orthodontist’s not achieving proper occlusion.

Regarding esthetics, Angle believed that ideal facial esthetics would be achieved only when the dentition was in proper occlusion. Instead of resorting to extractions, Angle advocated expansion of both dental arches to accommodate teeth in cases of overcrowding.

Case challenged Angle's concepts in the early 1900s by stating that esthetics and stability were compromised with Angle's unwavering nonextraction philosophy. Case argued that "new bone cannot be induced to grow beyond its inherent size which provides a sufficient reason to extract teeth in certain types of malocclusion."<sup>3</sup> Case focused on the spatial position of the maxillary and mandibular dentition and on the effects of the dentition on esthetics. Despite of Case's strong argument and reasoning, Angle's treatment philosophy dominated during the period between World Wars I and II.

After Angle's death in 1930, one of his students, Tweed, performed a groundbreaking experiment on his own relapsed nonextraction cases. Tweed practiced Angle's philosophy of the full complement of teeth for 6.5 years. At the end of this period, he recalled 70% of his treated patients and classified the results as being either successful or unsuccessful. To his surprise, his successes were less than 20% and the failures exceeded 80%. His criteria for success included the best balance and harmony of facial lines, stability of dentures after treatment, healthy tissues, and an efficient chewing mechanism.<sup>3</sup> Tweed re-treated, with the extraction of teeth, a number of patients who had been treated nonextraction and had relapsed. By extracting and realigning the teeth, he observed greater stability in the occlusion; he then made his results public. Tweed's recording of the results was one of the few documented instances of similar malocclusions being treated in a different manner. According to Tweed, the dentofacial

appearance after extraction was far more pleasing than those of similar patients being treated nonextraction. Fewer relapses were also observed.<sup>4,5</sup> The extraction philosophy was a pendulum swing for American orthodontics and reintroduced extraction therapy in the late 1940s. Another of Angle's students, an Australian, Raymond Begg, came to the same conclusion concerning the unstable results observed in nonextraction cases. He produced his own appliance, the Begg appliance, adapting it to extraction therapy.

By the early 1960s, orthodontic concepts concerning extraction therapy had been introduced. More than half of the American patients undergoing orthodontic treatment were referred for extraction of some teeth, usually first premolars, before treatment.<sup>6</sup>

Since the advocacy of extraction therapy in orthodontics by Tweed and Begg, there has been a steady decline in extraction treatment by orthodontic clinicians. Initially, extraction of teeth for orthodontic purposes was introduced as a means of enhancing stability. However, subsequent studies have shown that extractions per se do not necessarily ensure stability. Another consideration was the esthetic demands of an appearance-driven society. A recent study<sup>7</sup> showed that society prefers a fuller, broader smile, which, according to some, is easier to attain with nonextraction treatment. In the 1980s, reports of temporomandibular dysfunction associated with extraction also contributed to orthodontists' resisting extraction therapy.<sup>8</sup> Currently, there is a lack of agreement on the subject of extraction versus nonextraction treatment, particularly in borderline cases. Conflicting studies concerning esthetics and stability abound, resulting in numerous reports depicting harmful effects of extractions on occlusion, temporomandibular joints, profile, occlusal function, and stability.

The objective of the present study was to compare a sample of patients with mandibular crowding of 4 to 8 mm, measured on electronic models, that could benefit from either extraction or nonextraction therapy. The term “borderline” was used to classify these patients as to the amount of crowding present. The measurements studied were the mandibular transverse dimension, specifically intercanine dimensional changes and the incisor mandibular plane angle which was measured cephalometrically. The null hypothesis was that, in satisfactorily treated borderline extraction and nonextraction patients, changes in the intercuspid, interpremolar, and intermolar widths and in the incisor mandibular plane angle are not statistically significantly different. The results focus on the treatment outcome issue as it relates to expansion of intercanine dimension and proclination of mandibular incisors. If initial crowding is comparable in both the extraction and nonextraction groups, then statistically insignificant changes in the transverse mandibular dimensions and incisor mandibular plane angle between the two treatment modalities would strengthen the argument for nonextraction treatment in borderline crowded cases.

## LITERATURE REVIEW

There are several factors that should be of concern to the orthodontic clinician when planning the treatment of the borderline crowded patient. The effects of extraction versus nonextraction therapy on esthetics, health of the temporomandibular joint and surrounding soft tissues, mandibular intercanine dimension, mandibular incisor axial inclination, and long-term stability must be carefully considered before the final treatment decision is made.

The obvious goals of orthodontic treatment include attaining good facial esthetics, maintaining healthy surrounding soft tissues, achieving proper and functional occlusion, and finalizing a treatment result that is stable in the longterm. Whether teeth need to be extracted to achieve these goals has been debated over several decades. Obvious cases of severe crowding or minimal crowding leave most clinicians with little doubt about the correct treatment decision. However, the borderline crowded cases challenge the clinician to consider all of the treatment options and to base the decision to extract or not extract teeth on how treatment would affect these goals.

### Facial Esthetics

One of the goals of orthodontic treatment has always been to improve the esthetic problems that accompany many malocclusions. In fact, the historical “great debate” between Angle and Case concerning extraction therapy had an esthetic background.<sup>1</sup>

Facial esthetics is a personal and subjective concept that plays a role in an individual's psychological health. Self-esteem and social acceptance are affected by beauty and facial balance. Cultural trends similarly affect esthetics; the concept of beauty is constantly evolving.

Facial traits deemed important in facial beauty include mouth procumbency, lip fullness, mandibular contour, a chin that is wellproportioned, and proper alignment of the dentition.

The extraction versus nonextraction debate has been continually centered on the esthetic effects of both treatment modalities. Severe crowding and excessive dental protrusion may be obvious indicators for extraction; however, when the support for extraction is not as clear-cut, the decision becomes challenging. After Tweed showed the need for a well uprighted positioning of lower incisors onto supporting bone, tooth extraction became a routine procedure for many orthodontists. The extraction pendulum is currently swinging to the conservative side because of many factors such as the risk of possible litigation and the perceived detrimental effects of extractions on esthetics. The development of "new and improved" expansion techniques and early treatment options are contributing to the rise in popularity of nonextraction treatment therapy.

The esthetic effects of orthodontic therapy must be considered when deciding upon a treatment plan. Several investigators have compared extraction and nonextraction treatment effects on esthetics.

Ilken Kocadereli<sup>7</sup> evaluated the effects of orthodontic treatment on the facial profile, with or without the extraction of teeth. Included in the study were 40 patients who did not undergo extraction of teeth and 40 patients who underwent extraction of

maxillary and mandibular first premolars. Lateral cephalometric radiographs taken before and after orthodontic treatment were digitized and compared with each other. Measurement of the lips relative to Ricketts's<sup>9</sup> E-line and Burstone's<sup>10,11</sup> subnasale-soft tissue pogonion (Sn-Pog') line focused attention on the relationship of the nose, lips, and chin. In both groups in Kocadereli's study, the upper and lower lips were less protrusive after treatment. In the extraction group, the lips moved back in relation to the E-line and Sn-Pog' line. In the nonextraction group, there was less backward change of the lips than was found in the extraction group. The findings in the study by Kocadereli indicated that extraction of premolars may be appropriate when a decrease of lip procumbency is desired but that individual response must be considered. It would be advisable to inform the patient that there is an expected average change in lip procumbency but that a change is not certain and varies among individuals. In conclusion, the major soft tissue differences between the groups at the end of treatment were more retruded upper and lower lips in the extraction patients; however, the mean finished profile assessment for the extraction patients fell within the pleasing normal range, as measured by the Holdaway<sup>12,13</sup> H-line.

Bowman<sup>14</sup> found a conclusion to that of Kocadereli<sup>7</sup> concerning lip procumbency. Bowman examined the changes in facial esthetics resulting from extraction and nonextraction treatment and analyzed them as a function of pretreatment facial morphology. A sample of 120 Caucasian patients (70 extraction and 50 nonextraction) was randomly selected from Bowman's files. The effect of treatment on the facial profile was determined by a panel of observers that viewed profile tracings and recorded results on a visual analogue scale. The esthetic effect of treatment on the facial profile proved to



be a function of the type of treatment, the initial protrusion of the profile, and the observer's background. Extraction treatment had an esthetic effect that was proportional to the patient's pretreatment lip procumbency (lower lip to E-plane). In contrast, nonextraction treatment had little effect on facial esthetics, regardless of initial profile protrusion. The profiles of those whose lips were more than 2 to 3 mm behind the E-plane before treatment tended to be seen as having worsened as a result of premolar extraction. The conclusion of the study findings was that extraction treatment produces positive esthetic results for patients when the objective was to reduce lip procumbency.

Several investigations compared extraction and nonextraction effects on esthetics and found that extraction treatment did not have a negative effect on esthetics. Young and Smith<sup>15</sup> used cephalometric radiographs to examine soft tissue profiles of 198 orthodontic patients treated with full fixed appliances without extraction of any permanent teeth. The criteria for selection of cases and the methods of data collection were designed to allow comparison with data from Drobocky and Smith's<sup>16</sup> study on patients treated with extraction of four first premolars. Soft tissue changes were found to be smaller in the nonextraction patients, but variability was similar to that found in the four premolar extraction cases. Also, the undesirable facial changes were generally as common in the extraction and nonextraction cases. Drobocky and Smith presented evidence that does not support the general belief that extraction of premolars has a detrimental effect on esthetics. Their study included soft tissue profiles of 160 orthodontic patients who underwent first premolar extractions. The mean changes for the total sample included an increase of 5.2 degrees in the nasolabial angle and retraction of the upper and lower lips

of 3.4 and 3.6 mm to the E-line, respectively. A comparison with normal facial esthetics revealed that first premolar extractions did not typically result in a “dished-in” profile.

Ismail et al<sup>17</sup> compared the 3-dimensional effects on the face of extraction and nonextraction orthodontic treatment in patients with skeletal Class I patterns. Twelve patients were treated with extractions, and 12 were treated nonextraction. Study casts, lateral cephalometric radiographs, and optical surface scans were compared between the two groups. The 3-dimensional optical surface scans showed that faces in the nonextraction group became relatively more protrusive with treatment. In the extraction group, the concavity of the labiomental fold increased and the nonextraction group showed no change in this area. Also, the angle created by soft tissue nasion-subnasale-pogonion (angle of facial convexity minus the nose) increased in the extraction group and decreased in the nonextraction group.

Johnson and Smith<sup>18</sup> used standardized frontal photographs taken of the face during smiling to compare smile esthetics after orthodontic treatment with and without extraction of four first premolars. Thirty patients treated with extraction of four first premolars and 30 treated with full edgewise appliances without extractions were judged by a panel of 10 laypersons. There were no significant differences between the mean esthetic score of extraction patients and that of nonextraction patients. In the patients treated without extraction therapy, the results found for the variables that related to “buccal corridors” during smiling showed no correlation to the results found for those variables in the patients treated by extraction therapy. The results indicated that there was no predictable relationship between the extraction of premolars and the esthetics of the smile.

Luppanapornlarp and Johnson<sup>19</sup> assessed the skeletal, dental, and soft tissue changes that had occurred, both during treatment and in the 10-20 years thereafter of 238 edgewise patients. The sample was divided into extraction and nonextraction Class II patients. The premolar extraction therapy had a greater impact (by 2 to 3 mm) on the profile, and nonextraction treatment produced less of a change in profile convexity. It was stated that, contrary from what was expected, the nonextraction patients tended to have more concave faces, whereas the extraction patients more often had what nonextraction advocates call “nice, full, pleasing profiles.” This finding counters the popular rationale that extraction therapy causes “dished-in profiles.”

Paquette et al.<sup>20</sup> evaluated long-term effects of extraction and nonextraction edgewise treatments of 63 patients with Class II, division 1 malocclusions. Lateral cephalograms, study models, and a self-evaluation were used to determine the esthetic impact of treatment from 33 extraction and 30 nonextraction subjects. The long-term posttreatment interval average was 14.5 years. Premolar extraction therapy resulted in a greater reduction in hard and soft tissue protrusion. The posttreatment results showed essentially the same hard and soft tissue changes. Esthetically, profile convexity decreased in both groups. The 30 nonextraction patients did not rate their posttreatment appearance higher than the extraction subjects did, a finding contrary to what would be expected. The latter finding fails to support the general consensus among orthodontists that premolar extraction therapy causes “dished-in” profiles.

Bishara et al.<sup>21</sup> compared patients with Class II, division 1 malocclusion after extraction and nonextraction treatment to determine treatment and posttreatment changes in the facial and dental parameters. Their findings suggested that extraction and

nonextraction treatment plans based on proper diagnostic parameters do not have a generalized negative effect on the facial profile. This conclusion was supported by the results of a study by Nalchajian<sup>22</sup> that revealed that there were no subjective esthetic differences between the nonextraction and extraction patients before or after treatment. The orthodontic clinicians evaluating the posttreatment photographs in Nalchajian's study were correct 55% of the time when trying to determine whether a patient had had extraction treatment or nonextraction treatment, which is only slightly better than chance.

Dark buccal corridors have been linked to orthodontic treatment and are often regarded as an unattractive result of extracting premolars. The purpose of the study by Gianelly<sup>23</sup> was to compare anterior and posterior widths of dental arches after both extraction and nonextraction therapy to determine whether extraction treatment resulted in narrower dental arches and, by inference, larger dark shadows in the buccal corridor. Posttreatment study models of 25 patients who had four first premolar extractions and 25 patients treated without extractions were randomly selected and measured. All patients were treated with the edgewise technique, and the mandibular intercanine and intermolar widths of both groups did not differ statistically at the start of treatment. The results indicated that the average mandibular intercanine dimension was 0.94 mm larger in the extraction sample than in the nonextraction subjects. The maxillary arch width in both groups was essentially equal, which would cause the effect on smile esthetics to be similar. These results are similar to those of the study by Johnson and Smith<sup>18</sup> who evaluated smile esthetics after extraction and nonextraction treatment. Johnson and Smith found the intercanine width relative to visible dentition to be wider in the extraction patients. In borderline patients from another study,<sup>20</sup> the long-term increase of

the mandibular intercanine width in those treated by extraction therapy was 1.0 mm, whereas the increase in nonextraction sample was only 0.5 mm. These previous studies show that, contrary to popular belief, extraction treatment does not cause the dental arches to constrict and therefore does not result in dark, unesthetic buccal corridors.

### Temporomandibular Joint

When the orthodontist is deciding whether to extract teeth in borderline crowded patients, a review of expected treatment effects would not be complete without consideration of the health of the temporomandibular joint.

The prevalence of the signs and symptoms of temporomandibular disorders (TMD) has increased considerably in the past several decades. Emotional stress and more accurate diagnostic tools may be reasons for the trend, but a specific etiologic factor has not yet been detected.<sup>24</sup>

Occlusal factors as a contributing factor in TMD were first described by Costen<sup>25</sup> in 1934. There have been several theories since then that indicate that malocclusion is a risk factor for TMD. These theories lead the clinician to believe that an ideal occlusion will alleviate the signs and symptoms associated with this disease.

The possibility of orthodontics' being an etiologic factor in TMD has been at the forefront of dental discussions for the past 20 years. A lawsuit in the summer of 1987 sparked media attention and erroneous conclusions concerning orthodontics and TMD. It was concluded that orthodontics, specifically involving the extraction of teeth, led to the plaintiff's temporomandibular joint problems.<sup>26</sup> The jury found for the plaintiff and awarded her \$850,000. (With added costs, the total was 1.3 million dollars.)

In 1992 an article was published by Sadowsky<sup>27</sup> in which the literature on the risk of orthodontic treatment for producing TMD was thoroughly reviewed. Several studies were examined that addressed the question of a possible functional risk or benefit of orthodontic treatment on the temporomandibular joint and surrounding musculature. In the 14 studies reviewed, 1,300 orthodontic patients from different countries were evaluated who were treated with various techniques, including nonextraction and extraction therapies. The evidence was overwhelmingly in support of the fact that orthodontic treatment performed in children and adolescents generally is not a risk for future development of TMD.

There have been several investigations that confirm the conclusions published by Sadowsky.<sup>27</sup> Beattie et al.<sup>28</sup> identified retrospectively a sample of 63 patients who were considered borderline because they could have been treated either with or without extractions. They were recalled for long-term evaluation an average of 14 years after treatment to evaluate head and neck musculature and the temporomandibular joints. There were no significant differences between the extraction and nonextraction samples. The data failed to support the notion that premolar extraction causes temporomandibular disorder. Janson and Hasund<sup>29</sup> evaluated 60 orthodontic patients treated with different extraction protocols in 1981. It was concluded in this study that patients with severe malocclusion could be treated with no additional risk for developing temporomandibular joint dysfunction than the general population would face. Dibbets and Van Der Weele<sup>30</sup> evaluated the relationship between orthodontic treatment performed with extractions and TMD symptoms. The results of this 20-year longitudinal study revealed no relationship between the presence of TMD and orthodontic techniques and extractions in 172 patients

examined. Conti et al.<sup>31</sup> evaluated the symptoms of TMD in patients before and after orthodontic treatment. The sample consisted of 200 people divided according to type of malocclusion and type of treatment therapy. A questionnaire was used to classify TMD presence and severity, and a clinical examination of each patient was completed. The presence and severity of TMD did not show any relationship with either the type of orthodontic mechanics or the extraction protocol. It was concluded that orthodontic treatment was not associated with the presence of TMD.

Clinicians opposed to premolar extraction have claimed that extraction causes a decrease in the vertical dimension of occlusion and that this decrease causes the surrounding musculature to shorten, resulting in TMD.<sup>32,33</sup> Stagers<sup>34</sup> disproved this claim in a study that compared vertical dimension changes between extraction and nonextraction patients. It was found that, on average, orthodontic treatment produced a net increase in vertical dimension, with no significant difference between extraction therapy and nonextraction therapy.

Research has shown that condyle position varies in patients with or without TMD symptoms and does not accurately predict the position of the articular disk. However, it has been shown that symptomatic patients are more likely to have a posterior condyle position.<sup>35</sup> The purpose of a study by Major et al.<sup>36</sup> was to determine the effect of premolar extraction versus nonextraction orthodontic treatment on condyle position by utilizing pretreatment and posttreatment temporomandibular joint tomograms for each patient. The results showed an increased anterior joint space in the nonextraction group, with no other significant changes in condyle position in either group. In conclusion,

premolar extraction and fixed orthodontic treatment did not result in a statistically significant change in condyle position in Class I malocclusion.

It is apparent from the conclusions of the previously mentioned studies that orthodontic treatment does not result in an increased risk of developing TMD.

#### Mandibular Inter canine Dimension

The expected effect of orthodontic treatment on the arch form is an important factor for the clinician to consider when deciding whether or not to extract teeth on borderline crowded patients.

To properly determine what changes are occurring in the dental arch form as a result of orthodontic therapy, it is important to understand what changes normally occur without treatment. Bishara<sup>37</sup> evaluated changes in intercanine and intermolar widths over a 45-year span on a longitudinal basis. Twenty-eight male and 33 female infants were evaluated at approximately 6 weeks, 1 year, and 2 years of age. Fifteen male and 15 female subjects from the Iowa Facial Growth Study were also evaluated at ages 3, 5, 8, 13, 26, and 45 years. Maxillary and mandibular dental casts were measured for arch width. It was found that, between 6 weeks and 2 years of age, there were significant increases in the maxillary and mandibular anterior and posterior arch widths. Between 3 and 13 years of age in both maxillary and mandibular arches, intercanine and the intermolar widths increased significantly. After complete eruption of the permanent dentition, there was a slight decrease in the dental arch widths and that this decrease was greater in the intercanine area than in the intermolar area. Mandibular intercanine width, on average, was complete by 8 years of age or after the eruption of the four incisors. The



results indicated that, after the permanent dentition erupts, clinicians should expect either no changes or a slight decrease in arch width. Bishara<sup>37</sup> concluded that dental arch widths undergo changes from birth until the permanent dentition erupts completely. This conclusion would indicate that, on the basis of the existing data, the expansion of the dental arches beyond that attained after the eruption of the permanent dentition is most likely contraindicated.

In another study, normal arch changes were documented by Sillman.<sup>38</sup> This longitudinal study sample varied in age from birth to 25 years. An increase in intercanine width of 5.0 mm in the maxilla and 3.5 mm in the mandible in subjects from birth to 2 years of age was observed. After 2 years of age, the intercanine width increased in the maxilla until 13 years of age and increased in the mandible until 12 years of age. Canine widths remained stable after this time.

It has also been shown that mandibular intercanine dimension continues to change into adulthood. In a longitudinal study of arch size and form in untreated adults, Harris<sup>39</sup> found that mandibular intercanine width was not dependant on age. Arch widths increased over time, and arch length decreased. The changes altered arch shape toward shorter, broader arches. The conclusion reached was that changes during adulthood occur mostly during the second and third decades of life but do not necessarily cease after this time point.

Orthodontic treatment effects obviously have a tremendous impact on the arch form, specifically on the mandibular intercanine dimension. Several studies have shown that changes in this dimension tend to return to the original arch form and width. Uhde et al.<sup>40</sup> evaluated patients treated with or without extraction of four premolars. These

subjects were observed between 12 and 35 years of age after orthodontic therapy was complete. It was shown that the mean intercanine widths increased in both arches during treatment in all types of malocclusion and decreased after treatment toward their original widths. Mandibular intercanine width was found to decrease to close to or less than the original dimension.

There are numerous treatment techniques that produce intercanine expansion to resolve arch length deficiencies. These changes in anterior segment form may dictate long-term stability of the dentition and may require permanent retention. It has been shown repeatedly that the intercanine width decreases naturally over time in both treated and untreated individuals.<sup>41-47</sup> This dimension affects other aspects of the dental arch, such as the arch perimeter and the position of the incisors. Changes in these components in turn affect the intercanine width. The specifics of the interrelationship between intercanine width changes and other aspects such as incisal position and arch perimeter are not precisely known. Ricketts et al.<sup>48</sup> presented data showing that, for each millimeter of incisor advancement, the anterior arch perimeter is increased by 2 mm and that an increase of 1 mm in intercanine width creates a 1-mm increase in anterior arch perimeter.

Numerous studies have focused on the relapse potential when the intercanine dimension is expanded. Felton et al.<sup>49</sup> evaluated arch forms by using a fourth-degree polynomial function and found that mandibular arch form changes after nonextraction treatment were unstable. In that study, approximately 70% showed significant relapse posttreatment. De La Cruz et al.<sup>50</sup> used conic sections to depict arch forms in four premolar extraction cases 10 years postretention. Their study showed a correlation between the amount of treatment change and the tendency for relapse. Arch forms had a

tendency to go back to the original form. However, this relapse was difficult to predict and showed great variability.

In a study by BeGole et al.,<sup>51</sup> expansion of the dental arch was completed while trying to maintain the original arch form. Study models were used from before treatment, posttreatment, and postretention. Of the 76 individual arches, 53 were nonextraction and 23 had extractions. The mandibular canines showed significant relapse for both the extraction and nonextraction cases. As a result, the net change in arch dimension at the mandibular canines from pretreatment records to postretention records was not statistically significant in either group.

There have also been several studies that have yielded results that indicated instability with an extraction protocol when expansion was involved. Lee<sup>52</sup> completed a literature review of arch width and form in which he stated that expansion carried out in association with dental extractions is not generally likely to be a stable change. A prospective study by Huntley<sup>53</sup> showed that expansion of the lower arch is likely to be stable only in the absence of extraction.

Results of a study by Shearn and Woods<sup>54</sup> indicated that intercanine dimension changes were not much different between extraction and nonextraction groups of orthodontically treated patients. They investigated differences in lower arch-dimensional changes after orthodontic treatment that involved extraction of either lower first or lower second premolars. The sample included pretreatment and posttreatment records of 73 extraction cases, and it was found that the mean intercanine width in each group underwent little change.

### Mandibular Incisor Axial Inclination

Previous studies have indicated the importance of maintaining an acceptable range of mandibular incisor axial inclination throughout orthodontic treatment. The decision on whether extractions are necessary should be based, in part, on how treatment will affect the mandibular incisor axial inclination.

In 1941, Tweed concluded that the lower anterior teeth must be centered on the “ridge,” or body of the bone.<sup>55</sup> He claimed that, for orthodontic success to be achieved, the lower incisors must stand at right angles to the mandibular plane. If this condition was not possible with a full complement of teeth, extraction of premolars was permissible.

Brodie<sup>56</sup> disagreed with Tweed and concluded that axial inclination of the lower incisor varies greatly and is probably dependant on factors such as ethnic origin and genetics. Speidel and Stoner<sup>57</sup> used cephalometrics to study the axial inclination of the mandibular incisor to the mandibular plane and, like Brodie did, found a large range of variation.

Litowitz<sup>58</sup> cephalometrically evaluated 20 treated cases of malocclusion. He found that disturbance of the root apex or crown was followed by a return to the original position in almost every case, particularly if such movement had been in a labial direction. The measurements taken with plaster casts before and after treatment and after retention show that increases in lower arch length gained during treatment tended to decrease after retention and that expansion gained by treatment similarly showed a loss postretention.

Kocadereli<sup>7</sup> evaluated the differences between posttreatment axial inclinations of 40 nonextraction and 40 first premolar extraction patients. For the extraction group, mandibular incisors were more retroclined after treatment, but the mean posttreatment value for incisor inclination was close to normal. In the nonextraction group, the incisors were tipped forward. When compared with the normative value according to Steiner,<sup>59</sup> the posttreatment mean in the nonextraction group was excessive for incisor inclination.

In a study by Mills,<sup>60</sup> a few cases with skeletal deep bites and retroclined incisors in combination with a digit or lip entrapment habit showed stability after proclination. His results supported the theory that proclination may be successful if the incisors are initially retroclined because of an obvious factor and if that factor is eliminated with treatment.

Studies on mandibular incisor axial inclination are few, unfortunately. The previous studies are not in agreement concerning the acceptable range of mandibular incisor axial inclination changes with orthodontic treatment. However, it is apparent that there is a definite limit, and clinicians must consider long-term stability and periodontal health when evaluating that limit among orthodontic patients.

### Retention and Stability

The final and possibly most important factor for the clinician to consider when deciding upon whether to extract teeth in borderline crowded patients is long-term stability. It is generally agreed that retention of the orthodontic treatment result is perhaps the most difficult aspect but is also one of great significance. Normal

maturational changes and posttreatment tooth movement make retention challenging, to say the least.

Moyers defined retention as “The holding of teeth following orthodontic treatment in the treated position for the period of time necessary for the maintenance of the result.”<sup>61</sup> In 1934 Oppenheim was quoted as stating, “Retention is the most difficult problem in orthodontia; in fact it is the problem.”<sup>62</sup> The problem of retention lies in the instability of the teeth in the new position.

Basic concepts of retention have been established in orthodontics. In 1881 and 1891, respectively, Jackson<sup>63</sup> and Davenport<sup>64</sup> believed that occlusion determined retention. In 1899, Edward Angle<sup>65</sup> wrote about the priority of the lower arch in determining long-term stability of the entire dentition. Tweed<sup>66</sup> developed the concept that teeth should be positioned over basal bone to be stable. Rogers<sup>67</sup> introduced a balance of the teeth within the intra- and extraoral musculature in 1922. This concept was agreed upon by many others, including Brodie<sup>68</sup> and Strang.<sup>69</sup>

Arch width, especially the lower intercanine dimension, has been an area of controversy regarding retention. McCauley,<sup>70</sup> Strang,<sup>71</sup> and Riedel<sup>72</sup> felt that the mandibular intercanine and intermolar widths should remain as they originally presented. Strang,<sup>71</sup> Strang and Thompson,<sup>72</sup> and Howes<sup>73</sup> believed that, if canines are moved distal into extraction spaces, slight buccal expansion is permissible from a stability standpoint.

There have been multiple investigations that have compared extraction treatment and nonextraction treatment in terms of the stability and retention of the orthodontic result. Gardner and Chaconas<sup>74</sup> identified arch changes during treatment of 74 nonextraction cases and 29 extraction of first premolar cases. Intercanine, inter-first and

-second premolar, and inter-first molar widths were measured on pretreatment, posttreatment, and postretention mandibular casts. The results showed that the intercanine width was expanded during treatment but had a strong tendency to return to its original pretreatment values in both nonextraction and extraction cases. The intermolar width of nonextraction cases showed a significant increase in width with treatment. The extraction cases showed a significant decrease. However, there were no changes in either group postretention.

Little et al.<sup>45</sup> studied stability in a sample of mixed-dentition patients treated with nonextraction. Expansion techniques were used instead of extraction of premolars to align the dentitions. Postretention records of 26 patients were obtained a minimum of 6 years after retention. All patients showed a loss of treatment arch length increase, with only six showing any gain over pretreatment measurements. Width constriction and crowding of anterior teeth were consistent findings in the postretention records.

In the investigation by Luppapornlarp and Johnston,<sup>19</sup> the results favored extraction treatment over nonextraction. The extraction sample was able to accommodate the natural posttreatment arch-length reduction better than the nonextraction patients could accommodate this reduction. A long-term posttreatment arch-length reduction of 2-3 mm that was independent of treatment technique or malocclusion classification was documented in the study. The results showed that the extraction patients improved and that the nonextraction patients worsened. The fact that premolar extraction therapy seemed to show no apparent functional or esthetic deterioration in this study led to the conclusion that it is not necessary to seek nonextraction alternatives as has been the recent trend. It was also concluded that growth and treatment (either extraction or

nonextraction) have the same average effect on a wide range of patients. Therefore, clinically useful end of treatment predictions could be based on the initial shape of the face and on predictions of the mean increments of change resulting from growth and treatment.

Several authors documented relapse with any arch form change that varied greatly from the original arch form. De la Cruz<sup>50</sup> evaluated long-term changes in maxillary and mandibular arch form and found a general trend for arch form to return to pretreatment shape after retention. The greater the treatment change, the greater the tendency for postretention relapse was found to be. It was apparent from the results that the patient's pretreatment arch form was the best guide to future stability.

Miyazaki et al.<sup>75</sup> evaluated posttreatment stability of occlusion in adults and adolescents treated with four-premolar extractions at an average of 4 years posttreatment. The initial irregularity index comparison was not significant, and the initial intercanine width comparison was significant at the 5% level. The adolescent sample showed a significantly greater posttreatment increase in anterior crowding than the adult sample did; this may have been caused by continued developmental increases in crowding as a result of mandibular growth. Mandibular intercanine widths showed an increase with treatment but decreased after treatment in both groups. The posttreatment decrease observed in the adults was found to be correlated with the amount of expansion during treatment.

Vaden et al.<sup>76</sup> examined relapse in extraction treatment patients to determine the amount and rates of change in tooth positions and arch form and to assess which cephalometric changes after treatment could predict instability. All patients in this study



were treated with extraction of premolars and varied in malocclusion classification. The rate of change decreased with time; this finding supports the theory that most relapse occurs soon after treatment. Most of the posttreatment mandibular incisor irregularity was at the lateral incisor-canine contact area, with the canine slipping anteriorly to the lateral incisor. This drift of the canine may result from the canine's return to the pretreatment intercanine width.

Davis and BeGole<sup>77</sup> described the differences in expansion that occur between premolar extraction samples and nonextraction samples. During treatment, the nonextraction cases tended to expand from the canine posteriorly to the first molars. The extraction cases expanded also, but the second premolar and first molar transverse measurements narrowed in the mandibular arch. The canines in these instances were retracted into the extraction space, which is a wider part of the arch. The second premolars and first molars may have come forward; this possibility would explain the decrease in the transverse measurements. The intercanine widths on the nonextraction sample constricted more at posttreatment than they expanded during treatment. The arches in the extraction group also constricted during posttreatment, whether or not they had expanded.

Yavari et al.<sup>78</sup> searched dental casts for clinical predictors that may determine stability in mandibular anterior alignment. All 55 cases in this study were treated without extraction of permanent teeth. The patients were followed for at least 2 years postretention. Intercanine distance relapsed by approximately 80%, which was associated with an increase in irregularity index. The final mean value of intercanine distance was actually less than the pretreatment value was found to be. In contrast to

intercanine distance, intermolar expansion remained stable throughout the postretention period. This finding is supported in several investigations, which conclude that intermolar expansion has greater long-term stability than intercanine expansion does.<sup>79,80</sup>

Boley et al.<sup>81</sup> found satisfactory long-term results in a study that evaluated Class I, four-premolar extraction therapy results that had been out of retention a minimum of 5 years. Cephalometric and model analyses used to evaluate treatment and posttreatment tooth movements showed a significant decrease in irregularity index, with a slight posttreatment increase. Eighty percent of the patients had satisfactory mandibular incisor alignment over 10 years postretention, with none within the severe irregularity range. Arch lengths decreased during treatment because of molar protraction and incisor retraction, and mandibular arch length continued to decrease posttreatment as a result of mesial molar migration.

Blake and Bibby<sup>82</sup> completed a thorough review of the literature on long-term stability and retention; with over a hundred studies cited, the review highlighted factors that play a role in posttreatment crowding and orthodontic relapse. Although there are several conflicting theories, there are definitely many repeating consistencies among researchers. It is generally agreed that permanent retention is the only way to guarantee long-term posttreatment stability.<sup>44,46,83</sup> However, it is important to realize that there are many factors that contribute to relapse and that clinicians should attempt to minimize those factors as much as possible. The basic principles generally considered to minimize relapse are maintenance of the patient's pretreatment lower arch form, maintenance of the original intercanine dimension, and position of the lower incisor. A decrease in lower

intercanine width is generally acknowledged as being the most predictable of all orthodontic relapses.<sup>67,68,86-89</sup>

Housley et al.<sup>84</sup> investigated 29 nonextraction orthodontic cases at pretreatment, posttreatment, and an average of 6 years and 3 months postretention. This retrospective, longitudinal cephalometric and cast study evaluated changes produced by treatment and retention with the expanding mandibular lingual arch appliance in combination with fixed appliance therapy. Successful mandibular expansion was achieved with the lingual arch in less than 6 months in each case. Transverse expansion was shown to be more stable in the posterior of the arch than in the anterior segment. In this sample, only 8% of the arch width increase at the canines was still present after retention, but about 60-70% of the premolar and molar expansion remained. The conclusion was that mandibular intercanine width increase could only be permanently maintained by fixed retention. It seems that a person's inherent intercanine width is in balance with surrounding musculature and is unstable if altered with orthodontic treatment.

A study designed to quantify relapse<sup>85</sup> evaluated possible relationships between long-term postretention relapse of mandibular anterior crowding and between clinical factors such as increase in intercanine width, type of malocclusion, and final position of mandibular incisors. All 40 patients were treated without extractions in the mandibular arch with edgewise mechanics. The mean retention time was 2 years and 1 month, and the mean postretention observation period was 5 years. Lateral cephalograms and dental casts were used for measurements at pretreatment, posttreatment, and postretention. Little's irregularity index was determined, and any increase in this index from posttreatment to postretention was considered a relapse. Overall, intercanine width

showed a small increase during treatment but relapsed to the initial position. It must also be noted that some patients underwent interproximal stripping to correct crowding, and this procedure would influence postretention crowding and improve alignment stability.<sup>86</sup> The conclusion reached was that nonextraction treatment with mild to moderate crowding in the mandibular arch was associated with a mean relapse of 26.54% of Little's irregularity index in the long term.

It is obvious from decades of research that the association between relapse of the mandibular anterior segment and extraction protocol is a controversial subject. There are several factors involved, including crowding, malocclusion classification, final mandibular incisor inclination, treatment and retention time, and effects of surrounding musculature. There are extreme investigations<sup>46</sup> that provide data that imply that no clinical, dental cast, or cephalometric variable can predict relapse. However, others find definite correlations between clinical factors and relapse.<sup>40,87</sup> It seems that the responsibility of orthodontic specialists is to continue to seek answers to the retention and stability dilemma.

Tweed<sup>55</sup> summed it up best in his article summarizing his reasoning for extraction of teeth in certain instances. He claimed that normal occlusion in combination with a normal facial pattern is the ultimate in balance and harmony of the face. There are limitations to achieving this ideal combination over which an orthodontist has no control. However, clinicians should strive for occlusion, facial esthetics, health of surrounding tissues, and long-term stability that are as close to normal as possible and should continue to factor future stability issues into their initial treatment planning decisions.

A REEVALUATION OF MANDIBULAR INTERCANINE DIMENSION  
AND INCISAL POSITION

by

KELLY R. PAGE, P. LIONEL SADOWSKY,  
ANDRE FERREIRA, ALEX JACOBSON,  
AND FIROZ RAHEMTULLA

In preparation for *Angle Orthodontist*

Format adapted for thesis

## ABSTRACT

The purpose of the present study was to compare a sample of patients with borderline mandibular crowding (4 to 8 mm as measured on electronic models) who could benefit from either extraction or nonextraction therapy. Sixty patients treated in the orthodontics department of a university school of dentistry were evaluated. Thirty patients were treated with nonextraction therapy and 30 patients were treated with the extraction of premolar teeth (17 second premolars and 13 first premolars). Geodigm emodel software (Geodigm Corp., Chanhassen, Minn.) was used to compare mandibular arch width dimensional changes from pretreatment to after orthodontic treatment. Comparisons were made among the nonextraction group, the mandibular first premolar extraction group, and the mandibular second premolar extraction treatment group. In addition, pretreatment and posttreatment cephalograms were traced by using Dolphin Imaging software (Dolphin Imaging Systems, Chatsworth, Calif.). Comparisons were made among the treatment groups to evaluate the angle of the mandibular incisor in relation to the mandibular plane. The measurements made on the digital models showed more intercanine expansion in the extraction sample. However, the nonextraction sample had an increase in the incisor mandibular plane angle, whereas the extraction samples showed a decrease in the incisor mandibular plane angle.

## INTRODUCTION

The debate over extraction versus nonextraction therapy has been ongoing for decades. Angle's unwavering nonextraction philosophy was challenged by Case in the

early 1900s. Although though Case had a strong argument and valid reasoning, Angle's treatment philosophy dominated during the period between World Wars I and II.<sup>1</sup>

After Angle's death in 1930, one of his students, Tweed, re-treated many of his own previously treated nonextraction patients with the extraction of teeth because a number of patients who had been treated with nonextraction therapy had experienced relapse.<sup>2</sup> Tweed observed greater stability in the occlusion of his retreated patients and made these results public. Another of Angle's students, an Australian, Raymond Begg, came to the same conclusion concerning unstable results in nonextraction cases.<sup>2</sup> For this reason, Begg developed his own appliance, which involved the extraction of teeth.

Since the initial advocacy of extraction therapy in orthodontics by Tweed and Begg, there has subsequently been a steady decline in extraction treatment by orthodontic clinicians. Initially, the extraction of teeth for orthodontic purposes was introduced as a means of enhancing stability. It was later suggested that nonextraction therapy was more likely to enhance esthetics. Studies have shown a preference for a fuller, broader smile, which, according to some, seems to be easier to attain with nonextraction treatment.<sup>3</sup> Currently, opinions vary on the need for dental extractions in clinical orthodontics. There are many studies in the literature that reach differing conclusions on the extraction of teeth and on the subsequent effects of this treatment on esthetics, occlusion, temporomandibular joints, profile, occlusal function, and stability.<sup>3-7</sup>

#### Mandibular Inter canine Dimension

Bishara<sup>8</sup> evaluated changes in intercanine and intermolar widths over a 45-year span on a longitudinal basis and concluded that dental arch widths undergo changes

from birth until the permanent dentition erupts completely. It was shown by Sillman<sup>9</sup> that, at 2 years of age, the intercanine width increased in the maxilla until 13 years of age and in the mandible until 12 years of age and remained stable after this time. Harris<sup>10</sup> found that mandibular intercanine width was not dependant on age and concluded that changes during adulthood occur most during the second and third decades of life but do not necessarily cease after this time point. Several studies have shown that changes in mandibular intercanine dimension tend to return to the original arch form and width. Uhde et al.<sup>11</sup> evaluated patients treated with or without extraction of four premolars, and it was shown that the mean intercanine widths increased in both arches during treatment in all types of malocclusion and decreased after treatment toward their original widths.

There are numerous treatment techniques that produce intercanine expansion to resolve arch length deficiencies. These changes in anterior segment form may dictate long-term stability of the dentition and may require permanent retention. It has been shown repeatedly that the intercanine width decreases naturally over time in both treated and untreated individuals.<sup>12-18</sup> The results of several studies have revealed instability with an extraction protocol when expansion was involved. Lee<sup>19</sup> completed a literature review of arch width and form in which he stated that expansion carried out in association with dental extractions is not generally likely to be a stable change. A prospective study by Huntley<sup>20</sup> showed that expansion of the lower arch is likely to be stable only in the absence of extraction. In their study, Shearn and Woods<sup>21</sup> included pretreatment and posttreatment records of 73 extraction cases and found that the mean intercanine width in each group underwent little change.



### Mandibular Incisor Axial Inclination

In 1941, Tweed concluded that the lower anterior teeth must be centered on the “ridge,” or body of the bone<sup>22</sup> at right angles to the mandibular plane. Brodie<sup>23</sup> disagreed with Tweed and concluded that axial inclination of the lower incisor varies greatly and is dependant on factors such as ethnic origin and genetics. Speidel and Stoner<sup>24</sup> used cephalometrics to study the axial inclination of the mandibular incisor to the mandibular plane and, like Brodie did, found a large range of variation. According to Litowitz,<sup>25</sup> measurements taken on 20 plaster casts before and after treatment and after retention showed that increases in lower arch length gained during treatment tended to decrease after retention and that expansion gained by treatment similarly showed a loss postretention. Kocadereli<sup>26</sup> evaluated the differences between axial inclinations posttreatment of 40 nonextraction and 40 first premolar extraction patients. When compared with the normative value according to Steiner,<sup>27</sup> the posttreatment mean in the nonextraction group was excessive for incisor inclination. In a study by Mills,<sup>28</sup> a few cases with skeletal deep bites and retroclined incisors in combination with a digit or lip entrapment habit showed stability after proclination; these results support the theory that proclination may be successful if the incisors are initially retroclined because of an obvious factor and if that factor is eliminated with treatment. Earlier studies are not in agreement concerning the acceptable range of mandibular incisor axial inclination changes after orthodontic treatment. However, it is apparent that achieving long-term stability and periodontal health in orthodontic patients mandates that there be a definite limit to such changes.

The objective of the present study was to compare a sample of patients with mandibular crowding of 4 to 8 mm (measured on electronic models) who could benefit from either extraction or nonextraction orthodontic therapy. The term “borderline” was used to indicate that these patients could be treated with or without the extraction of teeth. The specific areas studied were the mandibular intercanine, the interpremolar, and the intermolar widths. In addition, the incisor mandibular plane angle as measured cephalometrically was evaluated. The null hypothesis was that, in satisfactorily treated borderline extraction and nonextraction patients, changes in the intercuspid, the interpremolar, the intermolar widths, and the incisor mandibular plane angle were not statistically significantly different.

#### MATERIALS AND METHODS

Approval for this study was granted by the Institutional Review Board for Human Use of the university at which the study occurred (Appendix). The sample consisted of the diagnostic records of 60 orthodontically treated patients from the orthodontic graduate program patient files at the university’s school of dentistry. All patients had been treated with an edgewise orthodontic appliance system. The study evaluated only mandibular arch parameters; therefore, all numbers recorded are for the mandibular arch only. Patients were selected by the following criteria: (1) must have completed orthodontic treatment, (2) displayed a full complement of teeth at postretention time (T2) (unless premolars teeth were extracted for orthodontic treatment), (3) had pretreatment (T1) and posttreatment (T2) emodels, (4) had pretreatment (T1) and posttreatment (T2) digital cephalograms digitized on Dolphin Imaging, (5) had 4 to 8

mm of mandibular crowding pretreatment (T1) as determined by measurement on emodels, and (6) had lower permanent cuspid teeth erupted at pretreatment (T1).

Patients were assigned to one of three groups: 0, no extractions; 4, extraction of mandibular first premolar teeth; or 5, extraction of mandibular second premolar teeth.

Table 1 shows the demographic data of the sample. The sample consisted of 42 patients with Angle Class I malocclusion, 15 patients with Angle Class II malocclusion, and 3 patients with Angle Class III malocclusions. Thirty patients (15 female and 15 male) were treated without the extraction of teeth, 13 patients (8 female and 5 male) were treated with the extraction of first premolar teeth; and 17 patients (13 females and 4 males) were treated with the extraction of second premolar teeth.

**TABLE 1. Descriptive Statistics: Sample Demographics**

Angle Classification	Nonextraction	Extraction	Total
Class I	25	17	42
Class II	4	11	15
Class III	1	2	3
Total	30	30	60
Gender			
Males	15	9	24
Females	15	21	36
Total	30	30	60

Table 2 shows the age range of the patient sample at the start of treatment (T1) and after completion of treatment (T2). The sample had a starting age range at T1 of 12-51 years for the patients treated with nonextraction and 10-22 years for patients treated with extraction of premolars. The age range at posttreatment (T2) was 13-52 years for the nonextraction patients and 12-25 years for patients treated with the extraction of teeth.

**TABLE 2.** Age range of the nonextraction and extraction sample groups

Time Points	Nonextraction Age Range (Years)	Extraction Age Range (Years)
T1 = pretreatment	12-51	10-22
T2 = posttreatment	13-52	12-25

### Data collection

This was a retrospective study of dental emodels and digitized lateral cephalograms of patients treated by graduate students. All digitized dental models (T1 and T2) had been prepared by the same company (Geodigm Corp., Chanhassen, Minn.). All digitized lateral cephalograms were taken directly in Dolphin Imaging software (Dolphin Imaging Systems, Chatsworth, Calif.) or were scanned into the software system. Magnification was corrected for differences between standard cephalogram film images that were scanned and digital images acquired by the imaging machine (Instrumentarium Orthoceph OC100D).

All pretreatment (T1) and posttreatment (T2) emodels were measured by using the emodel software program (Geodigm). The same operator made all of the dental cast measurements.

The following mandibular dental arch dimensions were measured:

1. Mandibular cusp tip intercanine width (ICC3): the distance between the cusp tips of the mandibular canines.
2. Mandibular gingival intercanine width (ICG3): the distance between the most labial aspect of the buccal surfaces of the mandibular canines.

3. Mandibular first interpremolar buccal cusp tip width (ICC4): the distance between the buccal cusp tips of the mandibular first premolar teeth.
4. Mandibular second interpremolar cusp tip width (ICC5): the distance between the buccal cusp tips of the mandibular second premolar teeth.
5. Mandibular first intermolar mesiobuccal cusp tip width (ICC6): the distance between the mesiobuccal cusp tips of the mandibular first permanent molar teeth.

In addition, the incisor mandibular plane angle (IMPA) was evaluated:

Measured on a lateral cephalometric, this was the angle between a line connecting menton to gonion and a line connecting lower incisor cusp tip to lower incisor root tip as defined in the Tweed analysis presented in the Dolphin Imaging software program (Dolphin Imaging Systems, Chatsworth, Calif.).

#### Data Analysis

The reproducibility of the measurements was evaluated by analyzing the differences between intercanine (ICC3) and IMPA measurements of the nonextraction sample (N=30) taken by one operator at three separate time intervals. The intraoperator reproducibility was measured by using the Pearson correlation coefficient ( $r=.99$ ). The results showed the measurements to be highly correlated, with no statistical difference between the measurements.

ANOVA was used to compare the means of the final mandibular arch dimensions among the nonextraction group, the first premolar extraction group, and the second

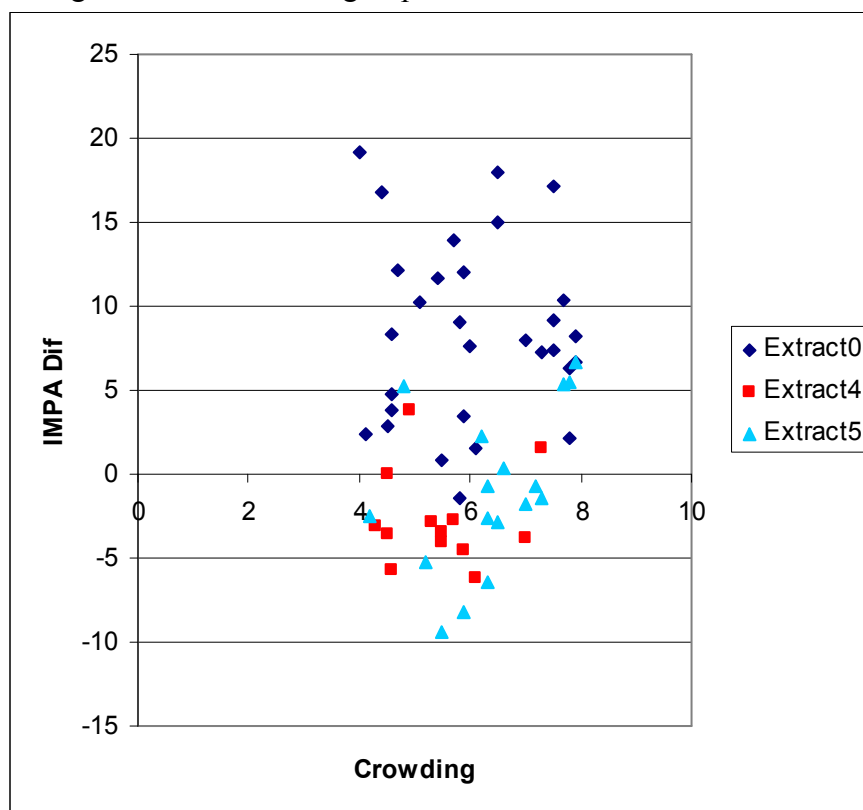
premolar extraction group. Table 3 lists the treatment outcome in each mandibular arch dimension measured. Dental arch expansion was assigned a positive number, and dental arch constriction was assigned a negative number. Incisor mandibular plane angle increase was assigned a positive number, whereas incisor mandibular plane angle decrease was assigned a negative number. The treatment outcome values were also assigned letters. Means with like letters indicate a statistical difference in means at  $P < .05$ . Means with unlike letters indicate that there is no statistical difference between the two values at  $P < .05$ .

## RESULTS

At the start of treatment, the entire sample of 60 patients had mandibular crowding of between 4 to 8 mm. Mandibular incisor axial inclinations measured before treatment were not statistically significantly different among the nonextraction group, the first premolar extraction group, and the second premolar extraction group.

The scattergram (Figure 1) plots the initial mandibular crowding in comparison with the IMPA changes after orthodontic treatment. The nonextraction sample demonstrates incisor proclination, whereas both extraction samples demonstrate either slight proclination or incisor retroclination.

FIGURE 1. Scattergram comparing change in IMPA with initial mandibular crowding among the three treatment groups.



IMPA = incisor mandibular plane angle; Extract 0 = nonextraction; Extract 4 = extraction of first premolars; Extract 5 = extraction of second premolars.

1. At T1, there was no statistically significant difference in the mean mandibular cusp tip intercanine width, mean mandibular gingival intercanine width, or incisor mandibular plane angle among the three treatment groups.
2. At T2, there was a statistically significant difference between the mean IMPAs for the nonextraction group and the first premolar extraction group.

3. At T2, there was a statistically significant difference between the mean IMPAs for the nonextraction group and the second premolar extraction group.
4. At T2, there was no statistically significant difference between the mean IMPAs of the first premolar extraction group and the second premolar extraction group.
5. From T1 to T2, intercanine width measured at mandibular intercanine cusp tips had expansion in all three treatment groups, but the expansion difference among them was not statistically significant.
6. From T1 to T2, intercanine width measured at the gingival margin was not statistically significantly different between the first premolar and the second premolar extraction groups.
7. From T1 to T2, intercanine width measured at the gingival margin had statistically significantly less expansion in the nonextraction group as compared with both the first premolar and the second premolar extraction groups.
8. From T1 to T2, the interpremolar expansion was not statistically significantly different between the nonextraction group and the second premolar extraction group.
9. From T1 to T2, the interpremolar expansion was statistically significantly different between the nonextraction group and the first premolar extraction group, with the second premolars constricting in the first premolar extraction group as they moved forward in the dental arch.



10. From T1 to T2, the intermolar measurements had slight expansion in the nonextraction group and was statistically significantly different from those measurements in both of the premolar extraction groups. The premolar extraction groups had statistically significantly similar constriction.
11. From T1 to T2, the IMPA of the nonextraction group had a large positive increase as compared with both extraction groups. In both extraction groups, the IMPA decreased by statistically significantly similar amounts. Table 4 shows the mean IMPA among the three groups at T1 and T2. The only group with a statistically significant change in IMPA was the nonextraction group. The mean IMPA was 89.45 degrees at T1 and 97.94 degrees at T2. The change in IMPA for T1 and T2 in the first premolar and second premolar extraction groups was not statistically significant.

**Table 3:** Change in Mandibular Arch Dimensions (From T1 to T2)

Extraction	Average (mean) Change in Measurement					
	ICC3	ICG3	ICC4	ICC5	ICC6	IMPA
None	0.97	0.77 (a,b)	1.91	2.89 (c)	0.73 (d,e)	8.49 (f,g)
4	1.18	2.22 (a)	Na	-1.05 (c)	-1.32 (d)	-2.65 (f)
5	1.16	2.13 (b)	2.97	Na	-2.54 (e)	-0.96 (g)

ICC3 = mandibular cusp tip intercanine width; ICG3 = mandibular gingival intercanine width; ICC4 = mandibular first interpremolar buccal cusp tip width; ICC5 = mandibular second interpremolar buccal cusp tip width; ICC6 = mandibular first intermolar mesiobuccal cusp tip width; IMPA = incisor mandibular plane angle. Positive values indicate expansion. Negative values indicate constriction. Na = teeth extracted.

**Table 4:** Mean IMPA among groups at T1 and T2

Group	Mean IMPA (Degrees)	Significance
Extraction = 0		
Time = 1	89.45	<i>P</i> <.0001
Time = 2	97.94	
Extraction = 4		
Time = 1	92.09	No statistical difference
Time = 2	89.44	
Extraction = 5		
Time = 1	93.44	No statistical difference
Time = 2	92.48	

0 = nonextraction; 4 = first premolar extraction; 5 = second premolar extraction; T1 = pretreatment; T2 = posttreatment; IMPA = incisor mandibular plane angle.

#### Summary of Results

In 30 borderline crowded patients treated with nonextraction therapy, all mandibular dental arch widths increased after orthodontic treatment. In comparison with the 30 patients treated with the extraction of premolars (17 second premolar extractions and 13 first premolar extractions), the nonextraction group had statistically significantly less expansion of the intercanine width at the gingival margin. In comparison with the second premolar extraction group, the nonextraction group had a large expansion in the first premolar width measurement, whereas the first premolars constricted in the second premolar extraction group. The intermolar width showed a slight expansion in the nonextraction group and significantly large constriction in both extraction groups. The IMPA showed a large increase in the nonextraction group and a decrease in both extraction groups. The nonextraction group was the only group with a statistically significant change in IMPA between T1 and T2.

## DISCUSSION

The goals of orthodontic treatment are generally agreed upon by the majority of clinicians. Each orthodontist strives to achieve in each patient good facial esthetics, maintenance of a healthy periodontium, optimal and functional occlusion, and stable long-term treatment results. Whether teeth need to be extracted to achieve these goals in each patient is debatable. In the past, clear-cut cases of severe crowding or minimal crowding have left little doubt about the correct treatment plan decision. Currently, there is a tendency toward preservation of tooth structure to achieve a more “full” smile. To achieve such a smile, even patients with significant crowding are being treated by the accommodation of all of their teeth.

Predictors of retention success have changed over time and have ranged from the final occlusal result<sup>29</sup> to the final position of lower teeth over basal bone.<sup>30</sup> Mandibular intercanine dimension has been regarded by most as being sacred.<sup>31-33</sup> Studies show that arch width, especially in the mandibular intercanine dimension, has a tendency to return to its original arch width after orthodontic treatment.<sup>16,34,35</sup> It seems that the greater the treatment change in arch form, the greater the tendency for postretention relapse is found to be.<sup>36</sup> The results in the present investigation show an increase in intercanine dimension in all three groups (nonextraction, first premolar extraction, second premolar extraction) with treatment. The difference in posttreatment change measured at the cusp tips of mandibular canines was not statistically significant among the groups; however, the treatment change measured at the gingival margin was statistically significant. The difference between results of measurements taken at cusp tips versus labial gingival margins may result from variations in pretreatment angulations of the canines. Labial

gingival margin measurements are a more accurate depiction of the widest possible width of the arch in this location.

The nonextraction group showed significantly less intercanine expansion than either the first premolar extraction group or the second premolar extraction group revealed. The greater expansion in the extraction groups may be explained by the possible lateral movement component of the canines as they are moved distally into the premolar extraction sites.

In a study that observed relapse in premolar extraction patients,<sup>37</sup> an interesting finding was that the rate of relapse decreased with time; this finding supports the theory that most change occurs soon after treatment. Many authors have reported on the phenomenon of late mandibular growth and resultant effect of this growth on orthodontic relapse.<sup>38-41</sup>

Uhde et al.<sup>42</sup> reported that, in a sample of nonextraction and extraction patients, the mean intercanine width increased in both groups and decreased after treatment toward its original width. Mandibular intercanine width was found to decrease to close to or past the original dimension. Studies have indicated that, regardless of treatment method (extraction or nonextraction), intercanine dimension tends to return to the original width. In the present sample of patients, the intercanine dimensional changes showed twice as much expansion at the buccal gingival margin in the extraction groups than were found at this margin in the nonextraction sample, and this finding would support the argument for treating borderline crowded patients with nonextraction therapy.

However, the data on IMPA introduce another dimension for orthodontists to consider when deciding whether to extract teeth in borderline crowded cases. In the

present study, the IMPA in the nonextraction group, the first premolar extraction group, and the second premolar extraction group were not statistically significantly different. At the end of orthodontic treatment, the nonextraction patients in the study had average IMPA increases nearly four times greater than those of the extraction patients. It seems that the crowding alleviation was the result of incisor proclination instead of mandibular intercanine expansion in the nonextraction group. Therefore, it is important for clinicians to consider the long-term stability of lower incisor proclination when deciding upon the type of treatment therapy in borderline crowded patients.

The history of lower incisor position dates from Charles Tweed and his evaluation of unsuccessful orthodontic treatment cases.<sup>29</sup> He noticed the degree of imbalance in his failures was in direct proportion to the extent to which the teeth were proclined mesially. Several authors followed with studies that related the mandibular incisor changes with treatment and postretention.<sup>43,44</sup> Margolis<sup>45</sup> related the mandibular incisor to the mandibular plane and showed that the angle changed after treatment and again postretention.

The pretreatment position of the mandibular incisors has been proven to be the best guide for predicting stability in a labiolingual position. Nance<sup>7</sup> ascertained that flaring the mandibular incisors is never a stable treatment technique. Brodie<sup>46</sup> and Cole<sup>47</sup> showed in nonextraction patients and extraction patients, respectively, that changes in axial inclination that result from orthodontics are unstable and that teeth tend to return to pretreatment positions. Weinberg and Sadowsky<sup>48</sup> showed that flaring of mandibular incisors relapsed posttreatment. It has also been shown repeatedly that the most frequent cause of mandibular incisor instability is intercanine width expansion with treatment.<sup>49-51</sup>

Studies overwhelmingly document the importance of maintaining the mandibular intercanine dimension.<sup>51-53</sup>

## CONCLUSIONS

Changes in the mandibular transverse dimension, specifically intercanine dimensional changes, were measured on digital casts and compared among treatment groups. Changes in IMPA during treatment were also evaluated and compared among the treatment groups. The following conclusions were drawn:

- From T1 to T2, expansion in the intercanine width at the gingival margin was significantly less in the nonextraction group than in both the first and the second premolar extraction groups, which were not statistically different from each other. As mentioned previously, the expansion of the canines in the extraction groups was likely caused by the distal movement of the canines into the extraction sites.
- From T1 to T2, the interpremolar expansion was not statistically different between the nonextraction group, and the second premolar extraction group but was statistically significant between the nonextraction group and the first premolar extraction group. As would be expected, the second premolars constricted significantly in the first premolar extraction group as a result of mesial movement into the first premolar extraction site.
- From T1 to T2, the intermolar measurements showed slight expansion in the nonextraction group; this expansion was significantly greater than that found in the premolar extraction groups, which showed

statistically similar constriction caused by the mesial movement of the molars into the premolar extraction sites.

- From T1 to T2, the IMPA of the nonextraction group showed more than four times the change that was found in the premolar extraction groups. The nonextraction group proclined an average of 8.5 degrees, whereas the extraction groups showed retroclination of the lower incisors. The first premolar extraction group had an average retroclination of 2.7 degrees, and the average retroclination of the second premolar extraction group was 0.97 degrees.
- The nonextraction group was the only group with a statistically significant change between T1 and T2 in IMPA.

In borderline crowded extraction situations, in which patients could benefit from either nonextraction or extraction therapy, it is important to consider all of the factors that affect long-term stability. The evaluation of the result of the different treatment modalities in this sample of patients, which initially had a statistically comparable amount of crowding, intercanine dimension and IMPA revealed that both methods produced treatment changes that have been well documented as being unstable. The nonextraction group did not have much intercanine expansion (less than 1 mm) but had a large amount of incisor proclination (8.5 degrees). The extraction groups had slight retroclination of mandibular incisors but a large increase in intercanine dimension, most likely resulting from the distal movement of the canine into a wider part of the arch. Whether this kind of intercuspid expansion, likely caused in large measure by cuspid

distalization, is as unstable as cuspid expansion caused by predominantly lateral cuspid movement is as yet undetermined.

An absolute conclusion about the best treatment modality for patients with borderline mandibular crowding may be difficult to formulate from the results of this study. The results can be tailored to support preconceived ideas toward extraction or nonextraction therapy. Expansion in the intercanine dimension of the mandibular arch because of distalization of the canines may or may not be stable in the longterm, but advancement of the mandibular incisors is definitely not stable. The clinician must factor long-term stability concerns into the treatment planning process. It is also important for the clinician to determine whether a decision to extract or not extract teeth in a patient with borderline crowding has been based on scientific data or is merely a practice management decision.

This study shows that, regardless of the decision on whether to extract premolars, treatment changes may introduce instability in one form or another. Orthodontists have a responsibility to educate and inform patients about the expected long-term treatment changes that may occur. If treatment outcome is to be permanently maintained, long-term to lifelong retention may need to be considered.



## REFERENCES

1. Proffit WR. *Contemporary Orthodontics*, 3<sup>rd</sup> ed. St. Louis: Mosby;2000.
2. Gianelly AA. *Extraction versus nonextraction*. Paris: SID Publisher;1995:175.
3. Kocadereli I. Changes in soft tissue profile after orthodontic treatment with and without extractions. *Am J Orthod Dentofacial Orthop*. 2002;122: 67-72.
4. Pollack B. Cases of note: Michigan jury awards \$850,000 in ortho case: a tempest in a teapot. *Am J Orthod Dentofacial Orthop*. 1988;94:358-359.
5. Little RM, Wallen TR, Riedel RA. Stability and relapse of mandibular anterior alignment-first premolar extraction cases treated by traditional edgewise orthodontics. *Am J Orthod*. 1981;80:349-365.
6. Little RM, Riedel RA, Stein A. Mandibular arch length increase during the mixed dentition: postretention evaluation of stability and relapse. *Am J Orthod Dentofacial Orthop*. 1990;97:393-404.
7. Nance HN. The limitations of orthodontic treatment. Part II. *Am J Orthod*. 1947;33:253-301.
8. Bishara SE. Arch length changes from 6 weeks to 45 years of age. *Am J Orthod Dentofacial Orthop*. 1997;111:401-409.
9. Sillman JH. Dimensional changes of the dental arches: longitudinal study from birth to 25 years. *Am J Orthod*. 1964;50:824-842.
10. Harris EF. A longitudinal study of arch size and form in untreated adults. *Am J Orthod Dentofacial Orthop*. 1997;111:419-427.
11. Uhde D, Sadowsky C, BeGole E. Long-term stability of dental relationships after orthodontic treatment. *Angle Orthod*. 1983;53:240-252.
12. Shields T, Little R, Chapko M. Stability and relapse of mandibular anterior alignment - a cephalometric appraisal of first premolar extraction cases treated by traditional edgewise orthodontics. *Am J Orthod*. 1984;87:27-38.
13. Sinclair P, Little R. Dentofacial maturation of untreated normal occlusions. *Am J Orthod*. 1983;83:114-123.
14. Sinclair P, Little R. Dentofacial maturation of untreated normals. *Am J Orthod*. 1985;88:146-156.

15. Little R, Riedel R, Artun J. An evaluation of changes in mandibular alignment from 10 to 20 years post-retention. *Am J Orthod Dentofacial Orthop.* 1988;93:423-428.
16. Little R, Riedel R, Stein A. Mandibular arch length increase during the mixed dentition: postretention evaluation of stability and relapse. *Am J Orthod Dentofacial Orthop.* 1990;97:393-404.
17. Little R. Stability and relapse of dental arch alignment. *Br J Orthod.* 1990;17:235-241.
18. Riolo ML, Moyers RE, McNamara JA, Hunter WS. An atlas of craniofacial growth: cephalometric standards from the University School Growth Study. Monograph 2. Center of Craniofacial Growth Development. Ann Arbor:University of Michigan, 1974.
19. Lee RT. Arch width and form: a review. *Am J Orthod Dentofacial Orthop.* 1999;115:304-13.
20. Huntley PN. The effect of archwires of identical form and dimension upon the mandibular arch of cases treated with the straight wire appliance. MSc, University of London 1989.
21. Shearn BN, Woods MG. An occlusal and cephalometric analysis of lower first and second premolar extraction effects. *Am J Orthod Dentofacial Orthop.* 2000;117:351-361.
22. Tweed CH. The application of the principles of the edgewise arch in the treatment of malocclusion. *Angle Orthod.* 1941;11.
23. Brodie AG. Does scientific investigation support the extraction of teeth in orthodontic therapy? *Am J Orthodont Oral Surg.* 1944;30.
24. Speidel TD, Stoner MM. Variation of mandibular incisor axis in adult "normal" occlusion. *Am J Ortho Oral Surg.* 1944;30.
25. Litowitz R. A study of the movements of certain teeth during and following orthodontic treatment. *Angle Orthod.* 1948;18:113-131.
26. Kocadereli I. Changes in soft tissue profile after orthodontic treatment with and without extractions. *Am J Orthod Dentofacial Orthop.* 2002;122:67-72.
27. Steiner CC. Cephalometrics in clinical practice. *Am J Orthod.* 1959;29:8-29.
28. Mills JRE. Long-term results of the proclination of lower incisors. *Br Dent J.*

- 1966; 120:355-363.
29. Tweed CH. Indications for the extraction of teeth in orthodontic procedure. *Am J Orthod.* 1944; 30:405-428.
  30. Oliver BM. The influence of lip thickness and strain on upper lip response to incisor retraction. *Am J Orthod Dentofacial Orthop.* 1982;82:141-149.
  31. Strang RHW. Factors associated with successful orthodontic treatment. *Am J Orthod.* 1952; 38:790-800.
  32. McCauley DR. The cuspid and its function in retention. *Am J Orthod.* 1944;30:196-205.
  33. Riedel RA. A review of the retention problem. *Angle Orthod.* 1960;30:179-194.
  34. Gardner SD, Chaconas SJ. Posttreatment and postretention changes following orthodontic therapy. *Angle Orthod.* 1976;46:151-161.
  35. Luppapornlarp S, Johnston LE. The effects of premolar-extraction: A long-term comparison of outcomes in “clear-cut” extraction and nonextraction Class II patients. *Angle Orthod.* 1993;63:257-272.
  36. De La Cruz A, Sampson P, Little RM, Artun J, Shapiro PA. Long-term changes in arch form after orthodontic treatment and retention. *Am J Orthod Dentofacial Orthop.* 1995;107:518-530.
  37. Vaden JL, Harris EF, Gardner RL. Relapse revisited. *Am J Orthod Dentofacial Orthop.* 1997;111:543-553.
  38. Behrents RG. Growth in the aging craniofacial skeleton. Monograph 17. Craniofacial Growth Series. Ann Arbor: Center for Human Growth and Development, University of Michigan, 1985.
  39. Bishara SE, Jakobsen JR, Treder JE, Stasi MJ. Changes in the maxillary and mandibular tooth size-arch length relationship from early adolescence to early adulthood. *Am J Orthod Dentofacial Orthop.* 1989;95:46-59.
  40. Humerfelt A, Slagsvold O. Changes in occlusion and craniofacial pattern between 11 and 25 years of age. *Trans Eur Orthod Soc.* 1972;1:113-122.
  41. Siatkowski RE. Incisor uprighting: mechanism for late secondary crowding in the anterior segments of the dental arches. *Am J Orthod.* 1974;66:398-410.
  42. Uhde D, Sadowsky C, BeGole E. Long-term stability of dental relationships after

- orthodontic treatment. *Angle Orthod.* 1983;53:240-252.
43. Fischer B. Recording tooth movement with the sectioned oriented mandibular radiogram and sectioned oriented cast. *Angle Orthod.*1943;11:333-336.
  44. Noyes HG, Rushing CH, Sims HA. The angle of axial inclination of human central incisor teeth. *Angle Orthod.* 1954;13:245-256.
  45. Margolis HF. Axial inclination of mandibular incisors. *Am J Orthodont Oral Surg.* 1943;29:112-123.
  46. Brodie AG. Cephalometric appraisal of orthodontic results. *Angle Orthod.* 1938;8:261-351.
  47. Cole HJ. Certain results of extraction in treatment of malocclusion. *Angle Orthod.* 1948;18:103-113.
  48. Weinberg M, Sadowsky C. Resolution of mandibular arch crowding in growing patients with Class I malocclusion treated nonextraction. *Am J Orthod Dentofacial Orthop.*1996;110:359-364.
  49. Yavari J, Shrouf MK, Russell CM, Haas AJ, and Hamilton EH. Relapse in Angle Class II Division 1 malocclusion treated by tandem mechanics without extraction of permanent teeth: a retrospective analysis. *Am J Orthod Dentofacial Orthop.* 2000;118:34-42.
  50. Artun J, Garol JD, Little RM. Long-term stability of mandibular incisors following successful treatment of Class II, Division 1, malocclusions. *Angle Orthod.*1996;66:229-238.
  51. Rossouw PE, Preston CB, Lombard CJ, Truter JW. A longitudinal evaluation of the anterior border of the dentition. *Am J Orthod Dentofacial Orthop.* 1993;104:146-52.
  52. Glenn G, Sinclair P, Alexander R. Nonextraction orthodontic therapy: posttreatment dental and skeletal stability. *Am J Orthod.*1987;92:321-328.
  53. Strang RHW. The fallacy of denture expansion as a treatment procedure. *Angle Orthod.* 1949;19:12-17.

## CONCLUSIONS

In this study, expansion in the intercanine width measured at the gingival margin was significantly less in the nonextraction group than in both first and second premolar extraction groups, which were not statistically different from each other.

The interpremolar expansion that occurred with treatment was not statistically different between the nonextraction group and the second premolar extraction group but was statistically significant between the nonextraction group and the first premolar extraction group. The second premolars constricted significantly in the first premolar extraction group.

The intermolar measurements showed slight expansion in the nonextraction group. This expansion was statistically significantly greater than intermolar measurements in the premolar extraction groups, which showed statistically significantly similar constriction in comparison with each other.

From T1 (pretreatment) to T2 (posttreatment), the incisal mandibular plane angle of the nonextraction group showed more than twice the absolute change in this angle than was found in the premolar extraction groups. The nonextraction group proclined an average of 8.5 degrees, and the extraction groups showed retroclination of lower incisors. The first premolar group retroclined 2.7 degrees, and the second premolar group retroclined 0.97 degrees.

The nonextraction group was the only group with a statistically significant change in incisal mandibular plane angle between T1 and T2.

In borderline crowded cases in which patients could benefit from either nonextraction therapy or extraction therapy, it is important to consider all of the factors that affect long-term stability. The evaluation of the result of the different treatment modalities in this sample of patients, who initially had a statistically comparable amount of crowding, intercanine dimension, and incisal mandibular plane angle, revealed that either method produced a treatment change that has been well documented in the literature as being unstable. The nonextraction group did not have much intercanine expansion (less than 1 mm) but had a large amount of incisor proclination (8.5 degrees). The extraction groups had slight retroclination of mandibular incisors but twice the increase in intercanine dimension (2.2 mm in the first premolar extraction group and 2.1 mm in the second premolar extraction group) that was found in the nonextraction group.

An absolute conclusion about the best treatment modality for patients with borderline mandibular crowding may be difficult to formulate from the results of this study. The results can be tailored to support preconceived ideas toward extraction or nonextraction therapy. Expansion in the intercanine dimension of the mandibular arch as a result of distalization of the canines may or may not be stable in the longterm, but advancement of the mandibular incisors is definitely not stable. Long-term stability issues must be included by the clinician in the treatment planning process. It is also important for the clinician to determine whether a decision to extraction or not extract teeth in a patient with borderline crowding has been based soundly on scientific data or is merely a practice management decision.

This study shows that, regardless of the decision about whether to extract premolars, treatment changes may introduce instability in one form or another.

Orthodontists have a responsibility to educate and inform patients of the expected long-term treatment changes that may occur. If treatment outcome is to be permanently maintained, long-term to lifelong retention may need to be considered.

## GENERAL LIST OF REFERENCES

1. Proffit WR. *Contemporary Orthodontics*, 3<sup>rd</sup> ed. St. Louis: Mosby; 2000.
2. Gianelly AA. *Extraction versus Nonextraction*. Paris: SID Publisher;1995:175.
3. Canut J. *Extraction versus Nonextraction: Esthetic Considerations*. Paris: SID Publisher;1995.
4. Tweed CH. Indicators for the extraction of teeth in orthodontic procedures. *Am J Oral Surg.* 1944;30:405.
5. Tweed CH. *Clinical Orthodontics*. Vol 1. St. Louis: Mosby;1966.
6. Proffit WR. *Contemporary Orthodontics*, 3<sup>rd</sup> ed. St. Louis: Mosby;2000.
7. Kocadereli I. Changes in soft tissue profile after orthodontic treatment with and without extractions. *Am J Orthod Dentofacial Orthop.*2002;122:67-72.
8. Pollack B. Cases of note: Michigan jury awards \$850,000 in ortho case: a tempest in a teapot. *Am J Orthod Dentofacial Orthop.*1988;94:358-359.
9. Ricketts RM. Esthetics, environment and the law of lip relation. *Am J Orthod* 1968;54:272-289.
10. Oliver BM. The influence of lip thickness and strain on upper lip response to incisor retraction. *Am J Orthod Dentofacial Orthop.* 1982;82:141-149.
11. Rains MD, Nanda R. Soft-tissue changes associated with maxillary incisor retraction. *Am J Orthod Dentofacial Orthop.*1982;81:481-488.
12. Holdaway RA. A soft-tissue cephalometric analysis and its use in orthodontic treatment planning. Part I. *Am J Orthod Dentofacial Orthop.*1983;84:1-28.
13. Holdaway RA. A soft-tissue cephalometric analysis and its use in orthodontic treatment planning. Part II. *Am J Orthod Dentofacial Orthop.*1984;85:279-293.
14. Bowman SJ. The esthetic impact of extraction and nonextraction treatments on Caucasian patients. *Angle Orthod.*2000;70:3-10.



15. Young TM. Effects of orthodontics on the facial profile: a comparison of changes during nonextraction and four premolar treatment. *Am J Orthod Dentofacial Orthop.* 1993;103:452-458.
16. Drobocky OB, Smith RJ. Changes in facial profile during orthodontic treatment with extraction of four first premolars. *Am J Orthod Dentofacial Orthop.* 1989;95:220-230.
17. Ismail SFH. Three-dimensional assessment of the effects of extraction and nonextraction orthodontic treatment on the face. *Am J Orthod Dentofacial Orthop.* 2002;121:244-256.
18. Johnson DK, Smith RJ. Smile esthetics after orthodontic treatment with and without extraction of four first premolars. *Am J Orthod Dentofacial Orthop.* 1995;108:162-167.
19. Luppanapornlarp S, Johnston LE. The effects of premolar extraction: a long term comparison of outcomes in “clear-cut” extraction and nonextraction Class II patients. *Angle Orthod.* 1993;63:257-272.
20. Paquette DE, Beattie JR, Johnston LE. A long-term comparison of nonextraction and premolar extraction edgewise therapy in “borderline” Class II patients. *Am J Orthod Dentofacial Orthop.* 1992;102:1-14.
21. Bishara SE, Cummins DM, Zahar AR. Treatment and posttreatment changes in patients with Class II, Division 1 malocclusion after extraction and nonextraction treatment. *Am J Orthod Dentofacial Orthop.* 1997;111:18-27.
22. Nalchajian N. Facial esthetics in borderline extraction and nonextraction patients. *Am J Orthod Dentofacial Orthop.* 2000;117:A1.
23. Gianelly AA. Arch width after extraction and nonextraction treatment. *Am J Orthod Dentofacial Orthop.* 2003;123:25-8.
24. Okeson JP. *Orofacial Pain. Guidelines for Assessment, Diagnosis and Management.* Chicago; Quintessence Publications; 1996:113-184.
25. Costen JB. Neuralgias and ear symptoms associated with disturbed function of the TMJ. *Ann Otol (St Louis).* 1934;43:1-15.
26. Pollack B. Cases of note: Michigan jury awards \$850,000 in ortho case: a tempest in a teapot. *Am J Orthod Dentofacial Orthop.* 1988;94:358-359.
27. Sadowsky C. The risk of orthodontic treatment for producing temporomandibular disorders: a literature overview. *Am J Orthod Dentofacial Orthop.* 1992;101:79-83.

28. Beattie JR, Paquette DE, Johnston LE. The functional impact of extraction and nonextraction treatments: a long-term comparison in patients with "borderline," equally susceptible class II malocclusions. *Am J Orthod Dentofacial Orthop*. 1994;105:444-9.
29. Janson M, Hasund A. Functional problems in orthodontic patients out of retention. *Eur J Orthod*. 1981;3:173-179.
30. Dibbets JMH, Van Der Weele LT. Long-term effect of orthodontic treatment, including extraction, on signs and symptoms attributed to TMD. *Eur J Orthod*. 1992;14:16-20.
31. Conti A, Freitas M, Conti P, Henriques J, Janson G. Relationship between signs and symptoms of temporomandibular disorders and orthodontic treatment: a cross-sectional study. *Angle Orthod*. 2002;73:411-417.
32. Witzig JW, Spahl TJ. The Clinical Management of Basic Maxillofacial Orthopedic Appliances. Littleton, (Mass):PSG Publishing;1987:161-216.
33. Bowbeer GR. The sixth key to facial beauty and TMJ health. *Function Orthod*. 1987;4:4-22.
34. Staggers JA. Vertical changes following first premolar extractions. *Am J Orthod Dentofacial Orthop*. 1994;105:19-24.
35. Ronquillo HI, Guay J, Tallents RH, Katzberg RW, Murphy W. Tomographic analyses of mandibular condyle position as compared to arthrographic findings of the temporomandibular joint. *J Craniomand Disorder*. 1988;2:59-64.
36. Major P, Kamelchuk L, Nebbe B, Petrikowsky G, Glover K. Condyle displacement associated with premolar extraction and nonextraction orthodontic treatment of Class I malocclusion. *Am J Orthod Dentofacial Orthop*. 1997;112:435-440.
37. Bishara SE. Arch length changes from 6 weeks to 45 years of age. *Am J Orthod Dentofacial Orthop*. 1997;111:401-409.
38. Sillman JH. Dimensional changes of the dental arches: longitudinal study from birth to 25 years. *Am J Orthod*. 1964;50:824-842.
39. Harris EF. A longitudinal study of arch size and form in untreated adults. *Am J Orthod Dentofacial Orthop*. 1997;111:419-427.
40. Uhde D, Sadowsky C, BeGole E. Long-term stability of dental relationships after orthodontic treatment. *Angle Orthod*. 1983;53:240-252

41. Shields T, Little R, Chapko M. Stability and relapse of mandibular anterior alignment - a cephalometric appraisal of first premolar extraction cases treated by traditional edgewise orthodontics. *Am J Orthod.* 1984;87:27-38.
42. Sinclair P, Little R. Dentofacial maturation of untreated normal occlusions. *Am J Orthod.* 1983;83:114-123.
43. Sinclair P, Little R. Dentofacial maturation of untreated normals. *Am J Orthod.* 1985;88:146-156.
44. Little R, Riedel R, Artun J. An evaluation of changes in mandibular alignment from 10 to 20 years post-retention. *Am J Orthod Dentofacial Orthop.* 1988;93:423-428.
45. Little R, Riedel R, Stein A. Mandibular arch length increase during the mixed dentition: postretention evaluation of stability and relapse. *Am J Orthod Dentofacial Orthop.* 1990;97:393-404.
46. Little R. Stability and relapse of dental arch alignment. *Br J Orthod* 1990;17:235-241.
47. Riolo ML, Moyers RE, McNamara JA, Hunter WS. *An atlas of craniofacial growth: cephalometric standards from the University School growth study.* Monograph 2. Center of Craniofacial Growth Development. Ann Arbor:University of Michigan, 1974.
48. Ricketts RM, Roth RH, Chaconas SJ, Schulhof RJ, Engel GA. *Orthodontic diagnosis and planning.* Denver: Rocky Mountain Data Systems;1982:194-200.
49. Felton JM, Sinclair PM, Jones DL, Alexander RG. A computerized analysis of the shape and stability of a mandibular arch form. *Am J Orthod Dentofacial Orthop.* 1987;92:478-483.
50. De La Cruz A, Sampson P, Little RM, Artun J, Shapiro PA. Long-term changes in arch form after orthodontic treatment and retention. *Am J Orthod Dentofacial Orthop.* 1995;107:518-30.
51. BeGole EA, Fox DL, Sadowsky C. Analysis of change in arch form with premolar expansion. *Am J Orthod Dentofacial Orthop.* 1998;113:307-315.
52. Lee RT. Arch width and form: a review. *Am J Orthod Dentofacial Orthop.* 1999;115:304-313.

53. Huntley PN. *The effect of archwires of identical form and dimension upon the mandibular arch of cases treated with the straight wire appliance*. MSc, University of London 1989.
54. Shearn BN, Woods MG. An occlusal and cephalometric analysis of lower first and second premolar extraction effects. *Am J Orthod Dentofacial Orthop*. 2000;117:351-361.
55. Tweed CH. Why I extract teeth in the treatment of certain types of malocclusion. *Alpha Omegan* 46:93-104.
56. Brodie AG. Does Scientific Investigation Support the Extraction of Teeth in Orthodontic Therapy? *American J Orthodont Oral Surg*. 1944;30:128-135.
57. Speidel TD, Stoner MM. Variation of mandibular incisor axis in adult “normal” occlusion. *Am J Orthodont Oral Surg* 1944;30:221-229.
58. Litowitz R. A study of the movements of certain teeth during and following orthodontic treatment. *Angle Orthod*. 1948;18:113-131.
59. Steiner CC. Cephalometrics in clinical practice. *Am J Orthod*. 1959;29:8-29.
60. Mills JRE. Long-term results of the proclination of lower incisors. *B Dent J*. 1966;120:355-363.
61. Moyers RE. *Handbook of Orthodontics for the Student and General Practitioner*. 3<sup>rd</sup> ed. Chicago, London, Boca Raton: YearBook Publishers; 1973.
62. Oppenheim A. *Int J Orthod*. 1934; 6:June.
63. Jackson VH. Methods of regulating teeth. *Dental Cosmos*. 1881; 33:1067-1082.
64. Davenport IG. Articulation of the teeth. *Int Dental J*. 1892; 13:1-8.
65. Angle EA. Classification of malocclusion. *Dental Cosmos*. 1899; 41:248-264.
66. Tweed CH. Indications for the extraction of teeth in orthodontic procedure. *Am J Orthod*. 1944; 30:405-428.
67. Rogers AP. Making facial muscles our allies in treatment and retention. *Dental Cosmos*. 1922; 64:711-730.
68. Brodie AG. The fourth dimension in orthodontics. *Angle Orthod*. 1954; 24:15-30.
69. Strang RHW. Factors associated with successful orthodontic treatment. *Am J Orthod*. 1952; 38:790-800.

70. McCauley DR. The cuspid and its function in retention. *Am J Orthod.* 1944;30:196-205.
71. Strang RHW. The fallacy of denture expansion as a treatment procedure. *Angle Orthod.* 1949;19:12-17.
72. Strang RHW, Thompson WM. *Text Book of Orthodontia.* 4<sup>th</sup> ed. Philadelphia: Lea and Febiger;1958.
73. Howes A. Expansion as a treatment procedure - where does it stand today? *Am J Orthod.* 1960;46:515-534.
74. Gardner SD, Chaconas SJ. Posttreatment and postretention changes following orthodontic therapy. *Angle Orthod.* 1976;46:151-161.
75. Miyazaki H, Motegi E, Yatabe K, Isshiki Y. Occlusal stability after extraction orthodontic therapy in adult and adolescent patients. *Am J Orthod Dentofacial Orthop.* 1997;112:530-537.
76. Vaden JL, Harris EF, and Gardner RL. Relapse revisited. *Am J Orthod Dentofacial Orthop.* 1997;111:543-553.
77. Davis LM, BeGole EA. Evaluation of orthodontic relapse using the cubic spline function. *Am J Orthod Dentofacial Orthop.* 1998;113:300-306.
78. Yavari J, ShROUT MK, Russell CM, Haas AJ, Hamilton EH. Relapse in Angle Class II Division 1 malocclusion treated by tandem mechanics without extraction of permanent teeth: a retrospective analysis. *Am J Orthod Dentofacial Orthop.* 2000;118:34-42.
79. Glenn G, Sinclair P, Alexander R. Nonextraction orthodontic therapy: posttreatment dental and skeletal stability. *Am J Orthod.* 1987;92:321-328.
80. Brodie AG. Cephalometric appraisal of orthodontic results. *Angle Orthod.* 1938;8:261-351.
81. Boley JC, Mark JA, Sachdeva RC, Buschang, PH. Long-term stability of Class I premolar extraction treatment. *Am J Orthod Dentofacial Orthop.* 2003;124:223-258.
82. Blake M, Bibby K. Retention and stability: a review of the literature. *Am J Orthod Dentofacial Orthop.* 1998;114:299-306.
83. Horowitz S, Hixon E. Physiologic recovery following orthodontic treatment. *Am J Orthod.* 1969;55:1-4.

84. Housley JA, Nanda RS, Currier GF, McCune DE. Stability of transverse expansion in the mandibular arch. *Am J Orthod Dentofacial Orthop.* 2003;124:288-93.
85. Freitas KM, Freitas MR, Henriques JFC, Pinzan A, and Janson G. Postretention relapse of mandibular anterior crowding in patients treated without mandibular premolar extraction. *Am J Orthod Dentofacial Orthop.* 2004;125:480-487.
86. Kuflinec MM. Effect of edgewise treatment and retention on mandibular incisors. *Am J Orthod.* 1975;68:316-322.
87. Kahl-Nieke B, Fischback H, Schwarze CW. Post-retention crowding and incisor. *Am J Orthod Dentofacial Orthop.* 1995;22:249-57.

APPENDIX

INSTITUTIONAL REVIEW BOARD FOR HUMAN USE APPROVAL FORM



Institutional Review Board for Human Use

Form 4: IRB Approval Form  
Identification and Certification of Research  
Projects Involving Human Subjects

UAB's Institutional Review Boards for Human Use (IRBs) have an approved Federalwide Assurance with the Office for Human Research Protections (OHRP). The UAB IRBs are also in compliance with 21 CFR Parts 50 and 56 and ICH GCP Guidelines. The Assurance became effective on November 24, 2003 and the approval period is for three years. The Assurance number is FWA00005960.

Principal Investigator: PAGE, KELLY R

Co-Investigator(s):

Protocol Number: X050815003

Protocol Title: Mandibular Intercanine Dimension: A Re-Evaluation

The IRB reviewed and approved the above named project on 08-23-05. The review was conducted in accordance with UAB's Assurance of Compliance approved by the Department of Health and Human Services. This Project will be subject to Annual continuing review as provided in that Assurance.

This project received EXPEDITED review.

IRB Approval Date: 8-23-05

Date IRB Approval Issued: 08-23-05

HIPAA Waiver Approved?: Yes

  
Marilyn Doss, M.A.  
Vice Chair of the Institutional Review  
Board for Human Use (IRB)

Investigators please note:

The IRB approved consent form used in the study must contain the IRB approval date and expiration date.

IRB approval is given for one year unless otherwise noted. For projects subject to annual review research activities may not continue past the one year anniversary of the IRB approval date.

Any modifications in the study methodology, protocol and/or consent form must be submitted for review and approval to the IRB prior to implementation.

Adverse Events and/or unanticipated risks to subjects or others at UAB or other participating institutions must be reported promptly to the IRB.



